

# Hiatal hernia types and their radiological diagnostics in patients with gastroesophageal reflux disease

A. O. Nykonenko<sup>1,E,F</sup>, Ye. I. Haidarzi<sup>1,A-F</sup>, T. V. Letkeman<sup>2,C</sup>

<sup>1</sup>Zaporizhzhia State Medical University, Ukraine, <sup>2</sup>Communal Non-Profit Enterprise "Zaporizhzhia Regional Clinical Hospital" of the Zaporizhzhia Regional Council, Ukraine

A – research concept and design; B – collection and/or assembly of data; C – data analysis and interpretation; D – writing the article; E – critical revision of the article; F – final approval of the article

**Key words:**  
gastroesophageal  
reflux disease,  
hiatal hernia,  
radiological  
diagnostics.

Zaporozhye  
medical journal  
2022; 24 (2), 168-175

\*E-mail:  
eig1981@yahoo.com

Gastroesophageal reflux disease (GERD) is one of the most common gastrointestinal pathology. In more than 80–90 % of patients, GERD is caused by the presence of hiatal hernia, leading to the failure of the lower esophageal sphincter. Therefore, experts increasingly agree that GERD can be effectively treated surgically in this case with a detailed diagnosis and assessment of hiatal hernia types. One of the most common methods for diagnosing hiatal hernia is radiological. But the results of the data interpretation obtained during preparation for surgical treatment are contradictory. This situation requires work continuation in this direction.

**The aim of the study** was to improve radiological diagnosis and conduct a detailed analysis of the hiatal hernia types in GERD patients.

**Materials and methods.** The examination results of 120 patients with GERD were analyzed. The mean age was  $55.1 \pm 10.7$ , there were 34 (28.3 %) men, 73 (71.7 %) women. In all patients, polypositional radiological examination ("Opera T 90сех", "General Medical Merate S.p.A.", Italy) of the esophagus, stomach with a water-soluble contrast agent (barium), photographic fixation, video recording and video analysis was performed. An internationally accepted classification was used to assess the hiatal hernia types. All patients were candidates for surgical treatment by laparoscopic crurography and Nissen or Toupet fundoplication. The results of the preoperative examination were specified intraoperatively. Statistical processing of the obtained results was performed using the Statistica for Windows 13.0 software package (StatSoft Inc., USA).

**Results.** In all patients, hiatal hernias were diagnosed. Type I hernias – in 94 (78.3 %) patients, type II hernias – in 3 (2.5 %), type III hernias – in 15 (12.5 %), type IV was detected in 8 (6.7 %) patients. The features of radiological diagnostic of hiatal hernia types were analyzed in detail, and steps to improve it were proposed. The issues of large and giant hernias diagnosis and definition were addressed. All results were illustrated with our own photographic material. A quantitative and qualitative assessment of the obtained results was carried out.

**Conclusions.** The leading role of various hiatal hernia types in the development of GERD has been suggested. Type I hiatal hernia has been presented as the most common among such patients. Detailed X-ray diagnostics with the use of photographic fixation, video recording and video analysis has been shown to be the important and effective method for determining the anatomical features of hiatal hernia types as the main factors of the esophagogastric junction disruption and, consequently, the development of GERD.

**Ключові слова:**  
гастроєзофагеальна  
рефлюксна  
хвороба, грижа  
стравохідного  
отвору діафрагми,  
рентгенологічна  
діагностика.

Запорізький  
медичний журнал.  
2022. Т. 24, № 2(131).  
С. 168-175

## Типи гриж стравохідного отвору діафрагми та їхня рентгенологічна діагностика в пацієнтів із гастроєзофагеальною рефлюксною хворобою

А. О. Никоненко, Є. І. Гайдаржі, Т. В. Леткеман

Гастроєзофагеальна рефлюксна хвороба (ГЕРХ) – одне з найпоширеніших гастроентерологічних захворювань. У більш ніж 80–90 % пацієнтів ГЕРХ зумовлена наявністю грижі стравохідного отвору діафрагми, що призводить до неспроможності нижнього стравохідного сфінктера. Тому все більше фахівців вважають, що ГЕРХ можна ефективно лікувати оперативним шляхом за умови детальної діагностики типів гриж стравохідного отвору. Один із найпоширеніших методів діагностики грижі стравохідного отвору діафрагми – рентгенологічний. Але результати інтерпретації рентгенологічних даних при підготовці до хірургічного лікування є суперечливими, а отже необхідне продовження досліджень у цьому напрямі.

**Мета роботи** – покращити рентгенологічну діагностику та здійснити детальний аналіз типів гриж стравохідного отвору діафрагми в пацієнтів із ГЕРХ.

**Матеріали та методи.** Проаналізували результати обстеження 120 хворих на ГЕРХ. Вік пацієнтів –  $55,1 \pm 10,7$  року, 34 (28,3 %) чоловіки, 73 (71,7 %) жінки. Усім хворим виконали поліпозиційне рентгенологічне дослідження стравоходу та шлунка з водорозчинною контрастною речовиною (барієм). Здійснили фотофіксацію, відеозапис і відеоаналіз, використали сучасне рентгенологічне обладнання «Opera T 90сех» («General Medical Merate S.p.A.», Italy). Для оцінювання типів гриж стравохідного отвору діафрагми використовували міжнародну загальноприйнятую класифікацію. Всі пацієнти були претендентами на хірургічне лікування в обсязі лапароскопічної круорографії та фундоплекції в модифікації Nissen або Toupet. Результати доопераційного обстеження підтверджували інтраопераційно. Статистично результати опрацювали, використавши пакет прикладних програм Statistica for Windows 13.0 (StatSoft Inc., США).

**Результати.** У всіх пацієнтів діагностували грижі стравохідного отвору діафрагми різних типів. Грижі I типу виявили в 94 (78,3 %) осіб, II типу – у 3 (2,5 %), III типу – в 15 (12,5 %), IV типу – у 8 (6,7 %) хворих. Здійснили детальний аналіз особливостей рентгенологічної діагностики типів гриж стравохідного отвору діафрагми, запропонували кроки щодо її поліпшення. порушено питання діагностики, визначення великих і гігантських гриж. Усі результати ілюстрували власним фотоматеріалом. Здійснили кількісне та якісне оцінювання результатів.

**Висновки.** Припустили, що провідну роль у розвитку ГЕРХ відіграють грижі стравохідного отвору діафрагми різних типів. Показано, що найбільш поширеним у таких пацієнтів є І тип. Детальна рентгенологічна діагностика з застосуванням фотофіксації, відеозапису та відеоаналізу – важливий та ефективний метод визначення анатомічних особливостей типів гриж стравохідного отвору діафрагми як провідного чинника порушення анатомії ділянки езофагогастрального з'єднання та, як наслідок, розвитку ГЕРХ.

Gastroesophageal reflux disease (GERD) is one of the most common gastroenterological diseases [1–4]. The number of detected GERD cases is steadily and rapidly increasing [2–6]. The issues of GERD pathophysiology and treatment have engendered progressively greater interest from specialists [2–4, 7–11].

Today, the opinions of leading experts in the field of gastroenterology and surgery concentrated to the definition of GERD as a polyetiological disease with various predisposing factors. However, many authors report that the main pathogenetic factor in the development of GERD is anatomical disruptions of the gastroesophageal junction. In particular, the presence of a hiatal hernia leads to the lower esophageal sphincter failure [8–10, 12–15].

Most scientists have assumed the hiatal hernia occurrence in more than 80–90 % of GERD patients as one of the main etiopathogenetic factors of its development [2–4, 10, 12, 14, 16–18]. In view of this, experts increasingly agree that GERD can be effectively treated surgically in this case [2, 4, 17–20].

At the same time, according to specialist, during preparation for surgical treatment, an objective assessment of the gastroesophageal junction state and visualization of the hiatal hernia features, associated with the development of GERD, are an important condition for the successful treatment of reflux disease [12, 14, 18, 21]. At first glance, one of the most simple and common method for diagnosing GERD and hiatal hernias today is the radiological method with an obligatory contrast barium swallow examination [2, 4, 22, 23].

However, in many guidelines for the diagnosis and treatment of GERD combined with a hiatal hernia, the specificities of this method use are not addressed in greater detail, without a clear description of illustrative materials and thorough radiological analysis of hernia types [2, 4, 7, 10, 12, 14, 18, 20, 24–26].

This results in diagnostic inaccuracies and misinterpretation of the obtained data in clinical practice and hence incorrect identification of indications for surgical treatment and poor postoperative outcomes.

Therefore, improvements to the targeted radiological analysis of the hiatal hernia types, causing the development of GERD, are relevant, and a more detailed study of their radiological features would contribute to effective differential diagnosis and clarification of indications for surgical treatment.

## Aim

The aim of this study was to improve radiological diagnosis and conduct a detailed analysis of the hiatal hernia types in GERD patients.

## Materials and methods

We performed a detailed analysis of various hiatal hernia types based on radiological data of 120 patients with GERD

who were admitted to the clinic for surgical treatment. The inclusion criteria were as follows: presence of GERD, consent to surgical treatment, absence of general contraindications to surgical treatment. The exclusion criteria were exacerbation of other chronic gastroenterological diseases such as pancreatitis, cholecystitis, hepatitis, gastritis, colitis, acute surgical pathology. The mean age was  $55.1 \pm 10.7$ , there were 34 men (28.3 %) and 73 (71.7 %) women.

To confirm the diagnosis of GERD, a questionnaire was completed using valid diagnostic and rating scales, esophagogastrosopy (“Evis Exera III, scope HQ 190”, “Olympus”, Japan), daily intraesophageal impedance-pH monitoring (“Acidogastrograph AG, Registrar 4pH-7Z-M”, “Start”, Ukraine), computed tomography (“Activion 16”, “Toshiba”, Japan) and the mandatory polypositional radiological examinations of the esophagus, stomach using a water-soluble contrast agent (barium) with photographic fixation, video recording and subsequent video analysis were performed for further detailed study of radiological features (“Opera T 90cex”, “General Medical Merate S.p.A”, Italy).

The radiological examination was carried out polypositionally in frontal, lateral and oblique anterior and posterior projections in the vertical position and in the Trendelenburg prone position followed by an examination in the initial vertical position with normal breathing, deep inspiration, and Valsalva maneuver. Radiological control to assess the contrast evacuation from the stomach was repeated after 30–60 minutes [23]. We paid attention to the contours of the esophagus, the thickness and wall elasticity, assessed the motor-evacuation function: tone, active movements, peristalsis, primary swallowing complex, the mucosal layer surface.

To determine the hiatal hernia types, we used the generally accepted classification dividing hiatal hernias into 4 types [2, 4, 12, 14]. Type I (sliding) hernia is characterized by the gastroesophageal junction displacement proximally through the esophageal hiatus and localization above the diaphragm. The stomach is in its usual position alongside the longitudinal axis with the esophagus, while the fundus of the stomach remains below the diaphragm (Fig. 1).

Type II (rolling) hernia is pure paraesophageal in which the gastroesophageal junction and cardia remain in the normal anatomical position, and a part of the stomach (fundus or body) herniates through the dilated esophageal hiatus, alongside the esophageal wall (Fig. 2).

Type III hernia (“mixed”) combines signs of both types I and II, where the gastroesophageal junction and a part of the stomach (fundus, body) herniate through the hiatus into the mediastinum. But the gastroesophageal junction is displaced alongside the longitudinal axis as in type I, and the most proximal part of the stomach, herniated into the mediastinum, is located above the gastroesophageal junction (Fig. 3).

Type IV is characterized by a herniation not only of a part of the stomach, but also of other abdominal organs

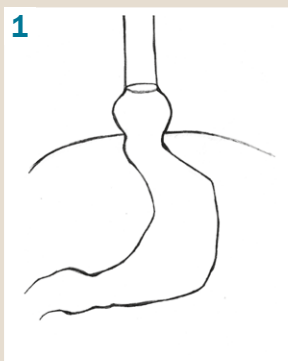


Fig. 1. Type I hiatal hernia.

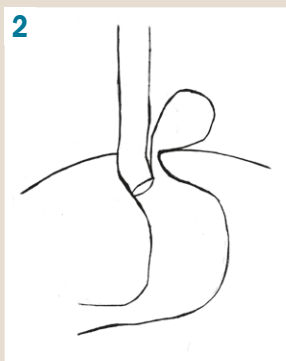


Fig. 2. Type II hiatal hernia.




Fig. 3. Type III hiatal hernia.

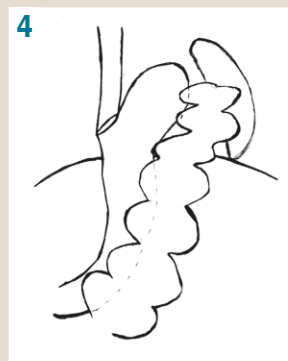
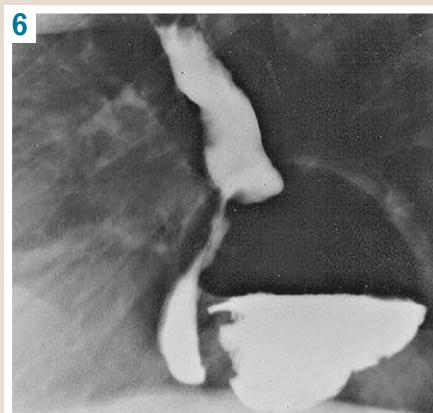


Fig. 4. Type IV hiatal hernia.

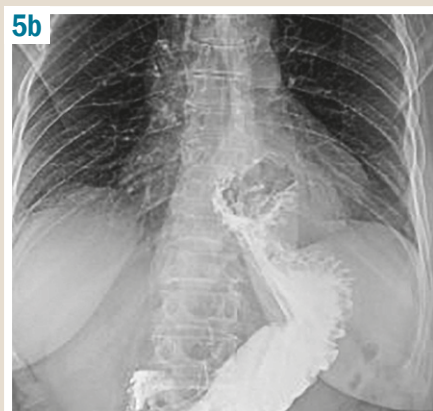
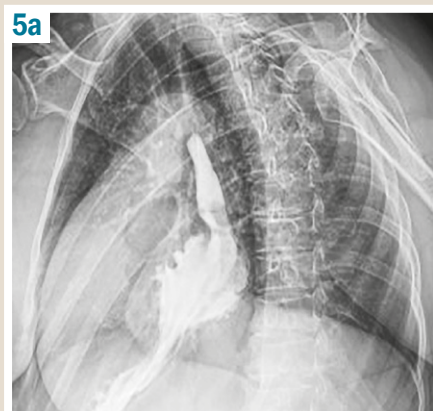
Fig. 5. Type I hiatal hernia:  
a: lateral position,  
b: frontal position.

Fig. 6. Type II hiatal hernia.



through the esophageal hiatus into the mediastinum, which can include the greater omentum, small and large intestine, spleen, and even the pancreas (Fig. 4).

All patients underwent planned surgical treatment of GERD to the extent of laparoscopic cruroraphy and Nissen or Toupet fundoplication. The results of the preoperative examination were mandatory specified intraoperatively.

Statistical processing of the obtained results was performed using Statistica for Windows 13.0 software package (StatSoft Inc., USA; license No. JPZ804I382130ARCN10-J).

### Results

As a result of the radiological examination and a detailed analysis of the obtained photo and video data, four types of hiatal hernia were diagnosed in all examined patients (100 %) with confirmed GERD. At the same time, type I hiatal hernia was diagnosed in the overwhelming majority – 94 (78.3 %) patients. Fig. 5 shows a radiograph of type I hiatal hernia.

In both frontal and lateral positions, the placement of the esophagogastric junction is visualized above the diaphragm in the mediastinum. In this case, the stomach is located lower along the nominal longitudinal axis.

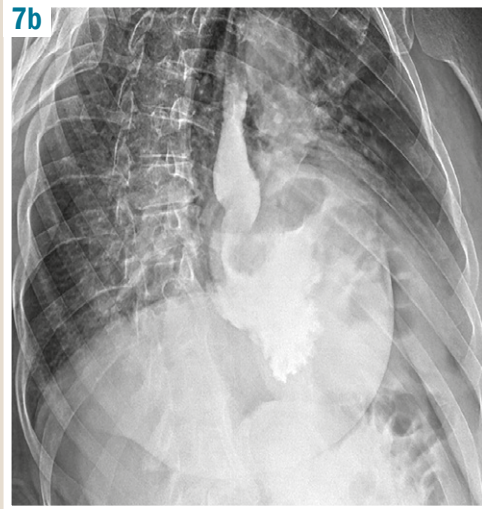
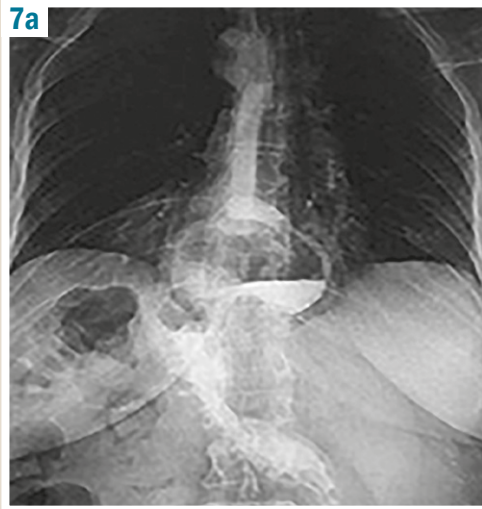
Paraesophageal hernias (Type II) were diagnosed in 3 (2.5 %) patients (Fig. 6).

In Fig. 6, the displacement of a part of the stomach (fundus, body) into the mediastinum is seen. The esophagogastric junction is in the normal anatomical position at the level of the esophageal hiatus. The stomach is located to the left of the esophagus and somewhat posteriorly, pushing the esophagus to the right, thereby complicating its mobilization and, accordingly, the operation.

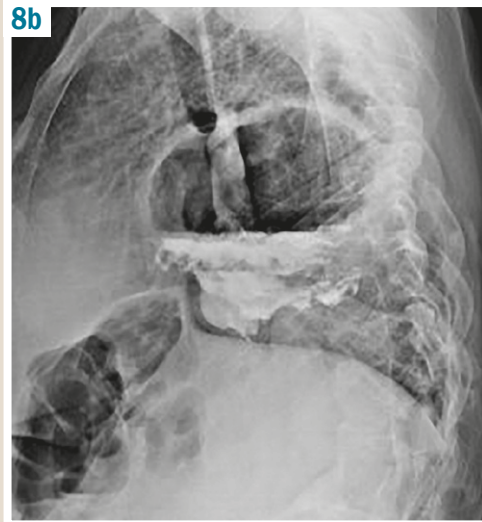
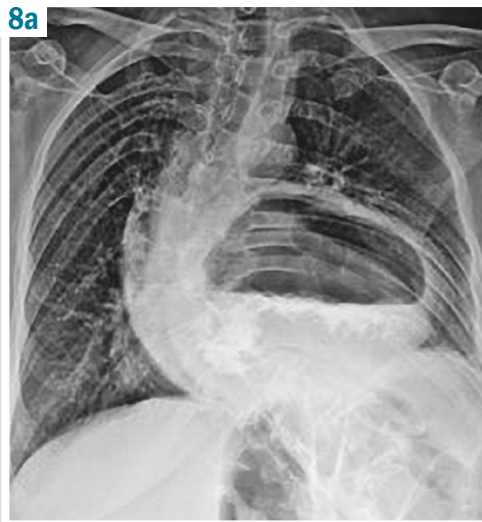
Type III hernias were diagnosed in 15 (12.5 %) patients with GERD (Fig. 7). This type represents mixed hernias and combines signs of both types I and II. In Fig. 7, the gastroesophageal junction is located above the normal level (the area of the diaphragmatic esophageal hiatus), but the part of the stomach (fundus, body) is elevated even higher in the mediastinal cavity parallel to the abdominal and thoracic esophagus.

Type IV hernia, which was detected in 8 (6.7 %) patients, is characterized by a displacement of other abdominal organs to the mediastinum in addition to the stomach: small or large intestine, greater omentum, spleen, and pancreas (Fig. 8).

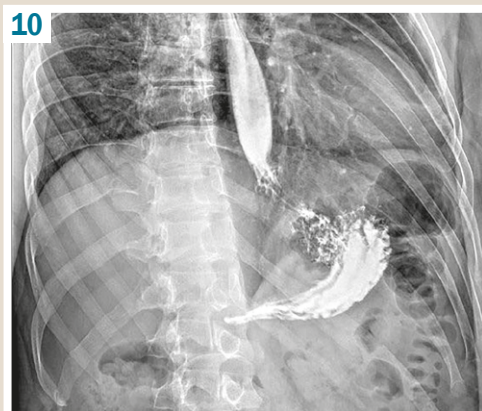
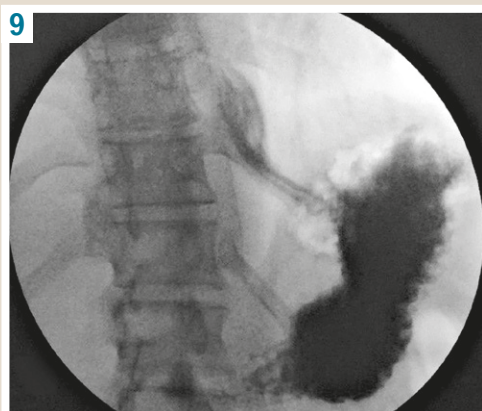



**Fig. 7.** Type III hiatal hernia:  
a: frontal position,  
b: lateral position.



**Fig. 8.** Type IV hiatal hernia:  
a: frontal position,  
b: lateral position.



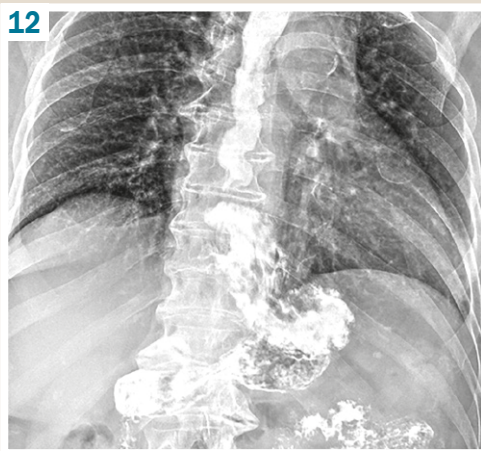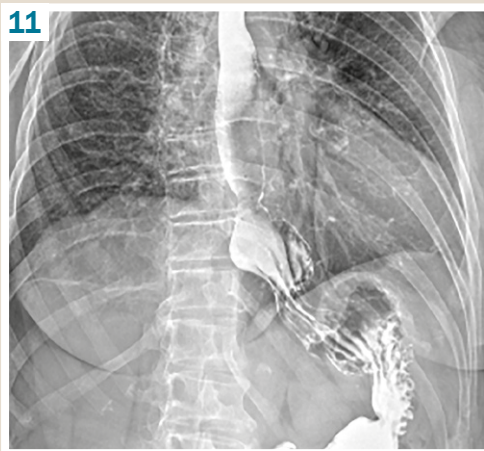
**Fig. 9.** Type I hiatal hernia  
(the abdominal esophagus  
is above the diaphragm).

**Fig. 10.** Type I hiatal  
hernia (cardiac folds of  
the stomach are visible  
above the diaphragm).

However, these hernias were not distinguishable radiographically from type I, II or III hernias, and it was not possible to visualize other organs that penetrate into the mediastinum through the esophageal orifice during radiological examination. Therefore, the diagnosis of type IV hernias was clarified by computed tomography or intraoperatively.

Interestingly, in our study, the differences in the size of type I hernias in GERD patients were expressed significant-

ly. We noticed that in 55 (58.5 %) patients with type I hernias, small hernias were detected when only the abdominal esophagus or the abdominal esophagus with the gastric cardia were displaced into the mediastinum. So, Fig. 9 shows only the abdominal esophagus displacement into the mediastinum without the gastric cardia, which with the gastric fundus is closely adjacent to the visceral surface of the diaphragm. The esophageal shortening is not detected.



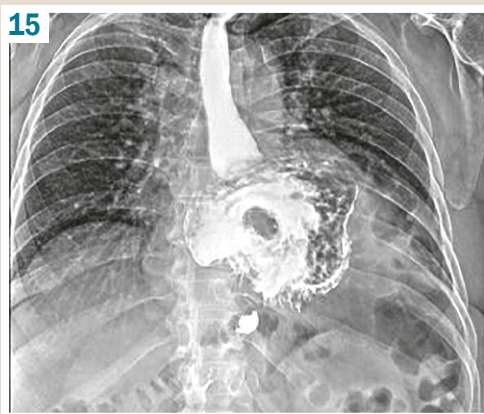
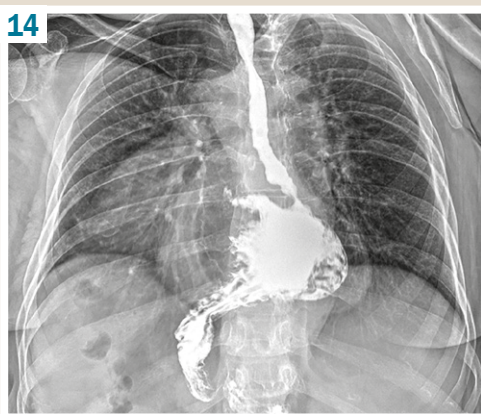
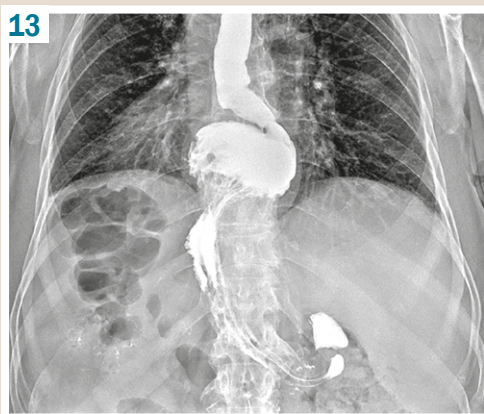
**Fig. 11.** Type I "esophago-cardio-fundal" hiatal hernia.

**Fig. 12.** Type I "esophago-cardio-fundal" hiatal hernia.

**Fig. 13.** Type III large-sized "esophago-cardio-fundal" hiatal hernia (back view).

**Fig. 14.** Giant hiatal hernia.

**Fig. 15.** Total gastric giant hiatal hernia. "Upside-down stomach".



At the same time, *Fig. 10* shows type I hernia, when the gastric cardia herniates into the mediastinum together with the abdominal esophagus, represented by gastric folds visible in the esophageal orifice. The esophagus is partly shortened.

In 39 (41.5 %) patients with type I hernias, "esophago-cardio-fundal" hernias were diagnosed, where a part of the fundus, the entire fundus or even a part of the stomach body was displaced into the mediastinum following the abdominal esophagus and the gastric cardia with characteristic gastric folds. The esophageal shortening was more expressed (*Fig. 11*). On the presented roentgenogram (*Fig. 11*), a small "esophago-cardio-fundal" hernia type I is detected, where a small part of the gastric fundus is

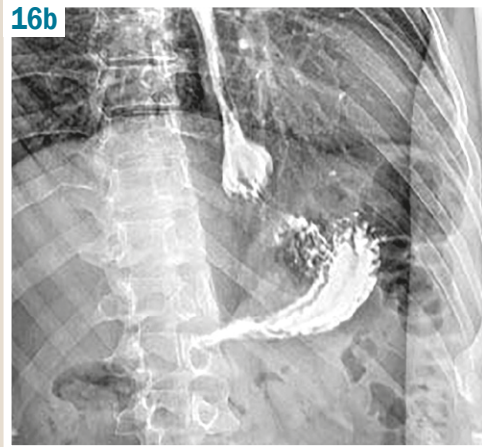
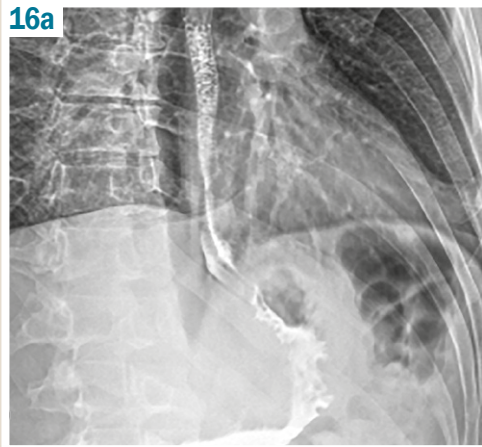
displaced into the mediastinum, and most of the fundus with a gas bubble and an a widened His's angle are seen in the abdominal cavity below the diaphragm.

*Fig. 12* shows a slightly larger "esophago-cardio-fundal" hernia, where most of the fundus is displaced into the mediastinum. In this case, the signs of the His's angle and a part of the stomach fundus are determined below the diaphragm, a gas bubble is expressed slightly, and the esophagus is even more shortened and twisted.

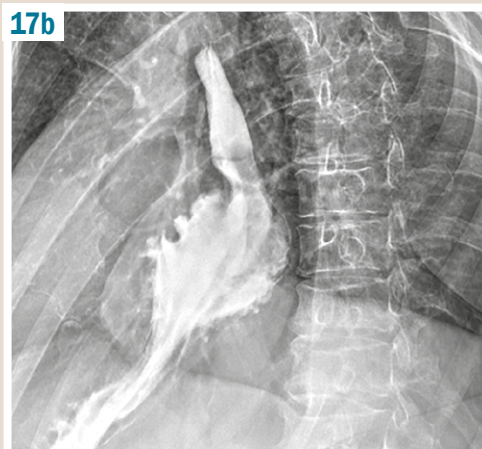
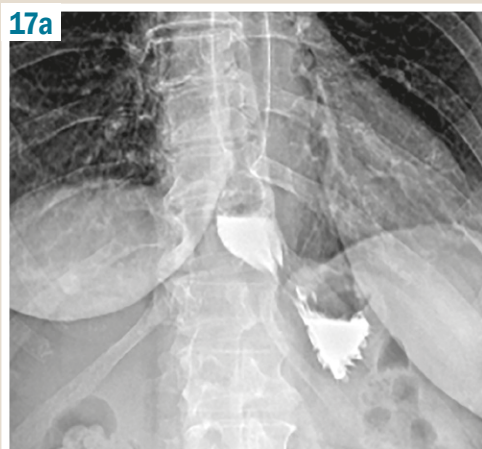
Thus, type I "esophago-cardio-fundal" hernias also vary in size depending on the size of the supradiaphragmatic part of the gastric fundus.

Large-sized "esophago-cardio-fundal" hernias were of particular note, since the fundus of the stomach was

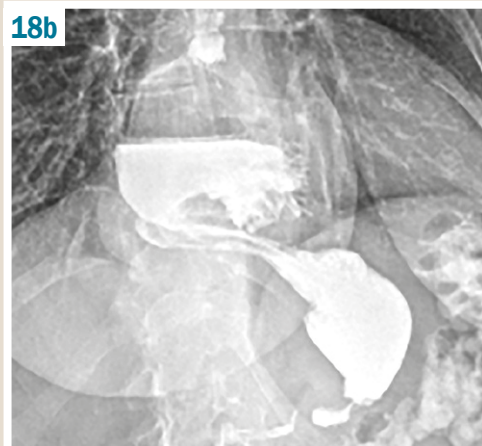
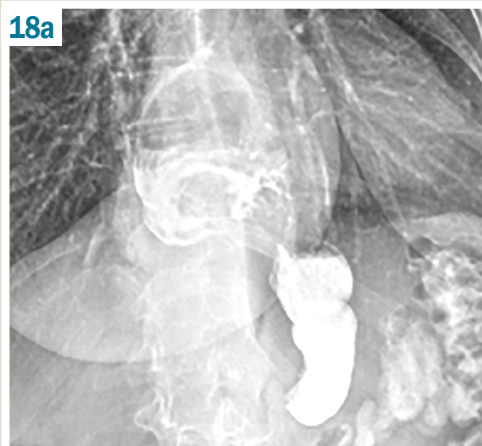




**Fig. 16.** Type I hiatal hernia:  
**a:** standing position,  
**b:** Trendelenburg position with the Valsalva maneuver.



**Fig. 17.** Type I hiatal hernia:  
**a:** standing position,  
**b:** Trendelenburg position with the Valsalva maneuver.



**Fig. 18.** GERD. Type III hiatal hernia:  
**a:** vertical position,  
**b:** Trendelenburg position.

completely displaced into the mediastinum, and the esophagus was sharply twisted or arcuate and closely adjoined the stomach wall. In this case, a characteristic feature was the absence of a gas bubble below the diaphragm and its supradiaphragmatic visualization.

Gastric folds were detected in the suprarenic space, there was a significant shortening of the esophagus and lateral or oblique union of the esophagus with the stomach. Often, the stomach looked like a “comma”, “club”, or “hourglass”, and the stomach body was narrowed at the esophageal orifice (Fig. 13).

Such large and very large “esophago-cardio-fundal” hernias corresponded to type III.

Subtotal gastric hiatal hernias and total gastric hiatal hernias were identified in 7 and 5 patients, respectively, and were characterized by the displacement of most stomach body (more than 1/2) up to the antrum or pylorus into the mediastinum (Fig. 14).

We classified such hernias as a separate group of giant hiatal hernias. Some authors classify such hernias as varieties of type III or IV, and some – as a separate, independent type [12,14,16,27,28].

In a total gastric giant hernia, the entire or nearly the entire stomach herniates into the mediastinum up to the pylorus. At the same time, when relocated to the thoracic cavity, the stomach reshapes into an inverted one, when the antrum and the body are located above the stomach fundus in the mediastinum, proximal to the gastroesophageal junction, resulting in a so-called "upside-down stomach". The esophagus can be shortened, but it can also be of normal length.

In 59 (49.2 %) patients, non-fixed hiatal hernias were detected, which were diagnosed only when patients were placed in a Trendelenburg position and an additional Valsalva maneuver was performed. Non-fixed hernias were most often observed in type I – in 58 (48.3 %) patients with GERD and in type IV – in 1 (0.8 %) patient. Non-fixed hiatal hernias were not detected in patients with types II and III hiatal hernia. *Fig. 16* shows a non-fixed hiatal hernia when a patient is examined in the Trendelenburg position with the Valsalva maneuver following the standing position.

In 41 (34.2 %) patients, partially fixed hiatal hernias were diagnosed, the size of which was visually more increased when the patients were in the Trendelenburg position with the Valsalva maneuver. Herewith, partially fixed hernias were observed in 31 (25.8 %) patients with type I hiatal hernia, in 1 (0.8 %) with type II, in 7 (5.8 %) with type III and in 2 (1.6 %) patients with type IV.

Only 20 (16.7 %) patients were diagnosed with completely fixed hiatal hernias, which practically did not change their anatomical position either in the vertical or in the horizontal position (*Fig. 18*).

Among them, type I hiatal hernia was diagnosed in 5 (4.2 %) patients, type II – in 2 (1.6 %), type III – in 8 (6.7 %) and type IV – in 5 (4.2 %) patients.

However, in all patients, an accurate diagnosis of the hiatal hernia type and the degree of its fixation was established only during the radiological examination using all the above diagnostic techniques after a detailed analysis of photo and video recordings, taking into account CT and intraoperative imaging.

## Discussion

Currently, the most common and generally accepted anatomical classification of hiatal hernias is that according to types I–IV [12,14,20,21]. Based on this classification, type I hiatal hernia represents the largest number of cases and is closely associated with GERD, with the remaining 5 % being types II–IV hiatal hernia taken together [14].

We have received much the same results through our approach to diagnostics. In our study, type I hiatal hernia was also diagnosed in the vast majority of patients with GERD – 94 (78.3 %). Whereas the rest of types II–IV accounted for 21.7 % of patients. Some discrepancy, represented by a shift towards paraesophageal (type II), mixed (type III) and combined (type IV) hernias (21.7 %) compared with the results presented by leading experts in the surgical treatment of GERD, may be due to obligatory use by us some additional diagnostic techniques in all patients.

Thus, polypositional video and photographic recording of an radiological image and a detailed radiological anatomical and physiological analysis of the hiatal hernia types after examination (in particular, viewing the passage of radiological contrast along the esophagus and stomach in a slow mode,

the use of the Valsalva maneuver), as well as the mandatory clarification of the diagnosis during the operation can increase diagnostic accuracy, especially types II, III and IV hernias, as well as successfully identify small, difficult to visualize, non-fixed (sliding) type I hernias. Detailed polypositional radiological anatomical analysis of small non-fixed (sliding) type I hernias using the Trendelenburg position and performing the Valsalva maneuver has increased the diagnosis of hiatal hernias in GERD patients up to 100 % in our study. At the same time, the literature also mentions 80–90 % or more of hiatal hernias in patients with GERD [16,20].

Thus, ours, as well as other research results obtained due to using the presented diagnostic techniques and confirmed by intraoperative data suggest that the development of GERD is extremely doubtful without disrupted anatomical relationships in the esophagogastric junction area that actually arise from hiatal hernia [2–4]. In view of so high indicator of the hiatal hernia presence in this category of patients, radiological diagnostics in GERD assumes a special diagnostic value and significantly influences the choice of surgical tactics [10,12,23].

Analyzing photo and video recordings in slow motion makes it possible not only to determine the type of hernia in detail and with high accuracy, but also to trace the changes that are invisible during the rapid passage of contrast through the esophagus and stomach, to conduct a detailed examination and assessment of the function, the esophageal contours, peristalsis, wall thickness and elasticity, the surface of the mucosal layer. Particular attention should be paid to the use of a polypositional examination, since the use of only a vertical direct projection can cause frequent diagnostic errors and lead to an incorrect interpretation of the obtained data.

In the course of our study, we noticed that the same types of hernias can differ significantly in size, shape, location. Like many surgeons specializing in the treatment of GERD, we have repeatedly drawn attention to the fact that the results of surgical treatment of GERD caused by a hiatal hernia often significantly depend on the hernia type and size [13,16,19]. Thus, a targeted detailed study of radiological anatomy and radiological physiology of the esophagogastric junction area using the presented diagnostic techniques is a prerequisite for accurate diagnosis of the hiatal hernia types, influencing the choice of optimal tactics for the successful treatment of GERD and prevention of its complications.

## Conclusions

1. The development of gastroesophageal reflux disease is mainly due to hiatal hernia leading to a violation of the normal anatomical relationships in the esophagogastric junction area in practically all patients.
2. Mandatory polypositional radiological diagnostics of the esophagogastric junction using respiratory techniques, video radiography with video capture and photographic fixation is an important and effective method for determining and differentiating the hiatal hernia types and their anatomical features.
3. Detailed radiological semiotics of the hiatal hernia types is the key to choosing the optimal tactics for the successful treatment of gastroesophageal reflux disease and the prevention of its complications.

**Conflicts of interest:** authors have no conflict of interest to declare.  
**Конфлікт інтересів:** відсутній.

Надійшла до редакції / Received: 06.10.2021  
Після доопрацювання / Revised: 12.10.2021  
Прийнято до друку / Accepted: 17.12.2021

### Information about authors:

Nykonenko A. O., MD, PhD, DSc, Professor, Head of the Head of the Department of Hospital Surgery, Zaporizhzhia State Medical University, Ukraine.

ORCID ID: [0000-0002-5720-2602](https://orcid.org/0000-0002-5720-2602)

Haidarzi Ye. I., MD, PhD, Associate Professor of the Department of Hospital Surgery, Zaporizhzhia State Medical University, Ukraine.

ORCID ID: [0000-0001-7211-1795](https://orcid.org/0000-0001-7211-1795)

Letkeman T. V., MD, Head of the X-ray Diagnostic Department, Radiologist of the Highest Category, Communal Non-Profit Enterprise "Zaporizhzhia Regional Clinical Hospital" of the Zaporizhzhia Regional Council, Ukraine.

### Відомості про авторів:

Никоненко А. О., д-р мед. наук, професор, зав. каф. госпітальної хірургії, Запорізький державний медичний університет, Україна.  
Гайдаржі Є. І., канд. мед. наук, доцент каф. госпітальної хірургії, Запорізький державний медичний університет, Україна.  
Леткеман Т. В., зав. рентгенодіагностичного відділення, лікар-рентгенолог вищої категорії, КНП «Запорізька обласна клінічна лікарня» ЗОР, Україна.

### References

- Pinto, D., Plieschnegger, W., Schneider, N. I., Geppert, M., Bordel, H., Höss, G. M., Ehrer, A., Wolf, E. M., Vieth, M., & Langner, C. (2019). Carditis: a relevant marker of gastroesophageal reflux disease. Data from a prospective central European multicenter study on histological and endoscopic diagnosis of esophagitis (histoGERD trial). *Diseases of the Esophagus*, 32(1), Article doy073. <https://doi.org/10.1093/dote/doy073>
- Horgan, S., & Fuchs, K. -H. (Eds.). (2020). *Management of Gastroesophageal Reflux Disease*. Springer, Cham. <https://doi.org/10.1007/978-3-030-48009-7>
- DeMeester, T. R. (2019). Chapter 16 – Etiology and Natural History of Gastroesophageal Reflux Disease and Predictors of Progressive Disease. In Charles J. Yeo (Ed.), *Shackelford's Surgery of the Alimentary Tract, 2 Volume Set*, (8th ed., Vol. 1, pp. 204-220). Elsevier. <https://doi.org/10.1016/b978-0-323-40232-3.00016-9>
- Schoppmann, S. F., & Riegler, M. (Eds.). (2021). *Multidisciplinary Management of Gastroesophageal Reflux Disease*. Springer, Cham. <https://doi.org/10.1007/978-3-030-53751-7>
- Richter, J. E., & Rubenstein, J. H. (2018). Presentation and Epidemiology of Gastroesophageal Reflux Disease. *Gastroenterology*, 154(2), 267-276. <https://doi.org/10.1053/j.gastro.2017.07.045>
- Chen, J., & Brady, P. (2019). Gastroesophageal Reflux Disease: Pathophysiology, Diagnosis, and Treatment. *Gastroenterology Nursing*, 42(1), 20-28. <https://doi.org/10.1097/SGA.0000000000000359>
- Vaezi, M. F. (Ed.). (2016). *Diagnosis and Treatment of Gastroesophageal Reflux Disease*. Springer, Cham. <https://doi.org/10.1007/978-3-319-19524-7>
- Akyüz, F., & Mutluay Soyer, Ö. (2017). How is gastroesophageal reflux disease classified? *Turkish Journal of Gastroenterology*, 28(1), S10-S11. <https://doi.org/10.5152/tjg.2017.04>
- Fadeenko, G. D., & Gridnev, A. E. (2014). *Gastroezofageal'naya refluksnaya bolezn': pishchevodnye, vnepishchevodnye proyavleniya i komorbidnost'* [Gastroesophageal reflux disease: esophageal, extraesophageal manifestations and comorbidity]. (A. N. Belovol, Ed.). OOO «Biblioteka «Zdorov'e Ukrainy». [in Russian].
- Smith, R. E., & Shahjehan, R. D. (2022). *Hiatal Hernia*. StatPearls Publishing. <https://www.ncbi.nlm.nih.gov/books/NBK562200/>
- Savarino, E., de Bortoli, N., De Cassan, C., Della Coletta, M., Bartolo, O., Furnari, M., Ottonello, A., Marabotto, E., Bodini, G., & Savarino, V. (2017). The natural history of gastro-esophageal reflux disease: a comprehensive review. *Diseases of the Esophagus*, 30(2), 1-9. <https://doi.org/10.1111/dote.12511>
- Memon, M. A. (Ed.). (2018). *Hiatal Hernia Surgery*. Springer, Cham. <https://doi.org/10.1007/978-3-319-64003-7>
- Schlottmann, F., Andolfi, C., Herbella, F. A., Rebecchi, F., Allaix, M. E., & Patti, M. G. (2018). GERD: Presence and Size of Hiatal Hernia Influence Clinical Presentation, Esophageal Function, Reflux Profile, and Degree of Mucosal Injury. *The American Surgeon*, 84(6), 978-982.
- Kohn, G. P., Price, R. R., DeMeester, S. R., Zehetner, J., Muensterer, O. J., Awad, Z., Mittal, S. K., Richardson, W. S., Stefanidis, D., Fanelli, R. D., & SAGES Guidelines Committee. (2013). Guidelines for the management of hiatal hernia. *Surgical Endoscopy*, 27(12), 4409-4428. <https://doi.org/10.1007/s00464-013-3173-3>
- Fuchs, K. H., Babic, B., & Fuchs, H. F. (2019). Esophageal Sphincters in Health and Disease. In C. J. Yeo, S. R. DeMeester, & D. W. McFadden (Eds.), *Shackelford's Surgery of the Alimentary Tract* (8th ed., Vol. 2, pp. 2-10). Elsevier.
- Fomin, P. D., Grubnik, V. V., Nikishaev, V. I., & Malinovsky, A. V. (2008). *Neopukhlevyye zabolevaniya pishchevoda [Non-neoplastic diseases of the esophagus]*. Biznes-Intellect. [in Russian].
- Slater, B. J., Dirks, R. C., McKinley, S. K., Ansari, M. T., Kohn, G. P., Thosani, N., Qumsey, B., Billmeier, S., Daly, S., Crawford, C., Ehlers, A. P., Hollands, C., Palazzo, F., Rodriguez, N., Train, A., Wassenaar, E., Walsh, D., Pryor, A. D., & Stefanidis, D. (2021). SAGES guidelines for the surgical treatment of gastroesophageal reflux (GERD). *Surgical Endoscopy*, 35(9), 4903-4917. <https://doi.org/10.1007/s00464-021-08625-5>
- Swanstrom, L. L., & Dunst, C. M. (Eds.). (2015). *Antireflux Surgery*. Springer, New York, NY. <https://doi.org/10.1007/978-1-4939-1749-5>
- Seo, H. S., Choi, M., Son, S. Y., Kim, M. G., Han, D. S., & Lee, H. H. (2018). Evidence-Based Practice Guideline for Surgical Treatment of Gastroesophageal Reflux Disease 2018. *Journal of Gastric Cancer*, 18(4), 313-327. <https://doi.org/10.5230/jgc.2018.18.e41>
- Fuchs, K. H., Babic, B., Breithaupt, W., Dallemagne, B., Fingerhut, A., Furnee, E., Granderath, F., Horvath, P., Kardos, P., Pointner, R., Savarino, E., Van Herwaarden-Lindeboom, M., Zaninotto, G., & European Association of Endoscopic Surgery (EAES). (2014). EAES recommendations for the management of gastroesophageal reflux disease. *Surgical Endoscopy*, 28(6), 1753-1773. <https://doi.org/10.1007/s00464-014-3431-z>
- Sfara, A., & Dumitrascu, D. L. (2019). The management of hiatal hernia: an update on diagnosis and treatment. *Medicine and Pharmacy Reports*, 92(4), 321-325. <https://doi.org/10.15386/MP-1323>
- Jobe, B. A., Richter, J. E., Hoppo, T., Peters, J. H., Bell, R., Dengler, W. C., DeVault, K., Fass, R., Gyawali, C. P., Kahrilas, P. J., Lacy, B. E., Pandolfino, J. E., Patti, M. G., Swanstrom, L. L., Kuriyan, A. A., Vela, M. F., Vaezi, M., & DeMeester, T. R. (2013). Preoperative Diagnostic Workup before Antireflux Surgery: An Evidence and Experience-Based Consensus of the Esophageal Diagnostic Advisory Panel. *Journal of the American College of Surgeons*, 217(4), 586-597. <https://doi.org/10.1016/j.jamcollsurg.2013.05.023>
- Koval', G. Yu. (Ed.). (2014). *Klinicheskaya rentgenanatomiya s osnovami KT-anatomii [X-ray Clinical Anatomy with the Basics of CT Anatomy]*. Meditsina Ukrainy. [in Russian].
- Katz, P. O., Gerson, L. B., & Vela, M. F. (2013). Guidelines for the Diagnosis and Management of Gastroesophageal Reflux Disease. *The American Journal of Gastroenterology*, 108(3), 308-329. <https://doi.org/10.1038/ajg.2012.444>
- Schlottmann, F., Andolfi, C., Herbella, F. A., Rebecchi, F., Allaix, M. E., & Patti, M. G. (2018). GERD: Presence and Size of Hiatal Hernia Influence Clinical Presentation, Esophageal Function, Reflux Profile, and Degree of Mucosal Injury. *The American Surgeon*, 84(6), 978-982.
- Aye, R. W., & Hunter, J. (Eds.). (2016). *Fundoplication Surgery*. Springer, Cham. <https://doi.org/10.1007/978-3-319-25094-6>
- Grubnik, V. V., Malinovsky, A. V., & Uzun, S. A. (2012). Laparoskopicheskaya plastika gryzh pishchevodnogo otverstyia diafragmy: analiz otdalennykh rezul'tatov v svete novoi klassifikatsii i obzor literatury [Laparoscopic repair of hiatal hernias: analysis of long-term results based on new classification and literature review]. *Ukrainskyi zhurnal khirurgii*, (4), 34-40. [in Russian].
- Malinovsky, A. V., & Grubnik, V. V. (2012). Dizain prospektivnykh randomizirovannykh issledovanii po laparoskopicheskoj plastike bol'shikh i gigantiskikh gryzh pishchevodnogo otverstyia diafragmy [Design of prospective randomized trials on laparoscopic repair of large and giant hiatal hernias]. *Ukrainskyi zhurnal khirurgii*, (4), 121-129. [in Russian].