

# The challenges in diagnosing hypertrophic cardiomyopathy in the presence of arterial hypertension: a clinical case

O. O. Khaniukov<sup>1B,F</sup>, L. V. Sapozhnychenko<sup>1A,B,D,E</sup>, O. V. Smolianova<sup>1B</sup> \*A,C,D

Dnipro State Medical University, Ukraine

A – research concept and design; B – collection and/or assembly of data; C – data analysis and interpretation; D – writing the article; E – critical revision of the article; F – final approval of the article

**Keywords:**  
hypertrophic cardiomyopathy, hypertension, clinical case, left ventricle hypertrophy.

Zaporozhye  
Medical Journal.  
2024;26(4):350-354

\*E-mail:  
smolyanova.ukr@gmail.com

**Aim.** To describe a clinical case and analyze the challenges in diagnosing hypertrophic cardiomyopathy (HCM) in a patient with concomitant arterial hypertension (AH).

**Materials and methods.** The article presents the clinical case of HCM in the patient with concomitant AH that was observed in an ambulatory setting in the Municipal Enterprise “Dnipropetrovsk Regional Clinical Center for Diagnostics and Treatment” of Dnipropetrovsk Regional Council.

**Results.** A 66-year-old woman N., diagnosed by her family physician with coronary artery disease (CAD): stable angina FC II, grade 2 AH, chronic heart failure FC II NYHA, was referred to a cardiologist because of experiencing exertional dyspnea, chest pain, and uncontrolled blood pressure despite treatment compliance.

Echocardiography identified concentric left ventricular hypertrophy with the left ventricular outflow tract (LVOT) obstruction (a mean gradient of 35 mmHg as per catheterization). Cardiac MRI confirmed the diagnosis and coronary angiography ruled out CAD. Adjustments to the treatment regimen, taking into account HCM with LVOT obstruction, effectively alleviated the patient's symptoms and stabilized her blood pressure.

**Conclusions.** It is especially important to follow the guidelines of AH management and perform echocardiography in all patients with high blood pressure, so as not to miss the signs of concomitant HCM, particularly with LVOT obstruction. In addition, in the case of HCM, it is necessary to timely detect, provide prevention and manage patients at risk for sudden cardiac death. Since HCM encompasses various diagnoses with different pathogenesis and distinct management, cardiac MRI, enzymatic or genetic testing may be needed according to guidelines.

As HCM is a relatively common inherited cardiac disease, general practitioners could often encounter such patients in everyday clinical practice. Hence, they should have a certain suspicion of this diagnosis in persons with AH whose left ventricular mass meets the criteria for HCM.

**Ключові слова:**  
гіпертрофічна кардіоміопатія, артеріальна гіпертензія, клінічний випадок, гіпертрофія лівого шлуночка.

Запорізький  
медичний журнал.  
2024. Т. 26, № 4(145).  
С. 350-354

## Складнощі діагностики гіпертрофічної кардіоміопатії за наявності артеріальної гіпертензії: клінічний випадок

О. О. Ханюков, Л. В. Сапожниченко, О. В. Смолянова

**Мета роботи** – описати клінічний випадок і проаналізувати складнощі діагностики гіпертрофічної кардіоміопатії (ГКМП) у хворого з супутньою артеріальною гіпертензією (АГ).

**Матеріали і методи.** Описано клінічний випадок ГКМП у хворої з супутньою АГ, яка перебувала під амбулаторним спостереженням у Комунальному підприємстві «Дніпропетровський обласний клінічний центр діагностики та лікування» Дніпропетровської обласної ради.

**Результати.** Хвора Н. – жінка 66 років, у якої сімейний лікар діагностував ішемічну хворобу серця (ІХС): стабільну стенокардію II ФК, АГ 2 ст., хронічну серцеву недостатність II ФК NYHA. Пацієнтка направлена до кардіолога через задишку під час фізичного навантаження, біль у грудях і неконтрольований артеріальний тиск, незважаючи на дотримання призначеного лікування.

На ехокардіографії виявлено концентричну гіпертрофію лівого шлуночка з обструкцією вихідного тракту лівого шлуночка (середній градієнт – 35 мм рт. ст., за даними катетеризації). Показники, встановлені під час МРТ серця, підтвердили діагноз, а результати коронарографії дали змогу виключити ІХС.

Коригування схеми лікування пацієнтці, враховуючи наявність ГКМП з обструкцією вихідного тракту, ефективно полегшило симптоми та стабілізувало артеріальний тиск.

**Висновки.** У хворих із високим артеріальним тиском вкрай важливо дотримуватися рекомендацій щодо ведення АГ і виконувати ехокардіографію всім пацієнтам, аби не пропустити ознак супутньої ГКМП, особливо з обструкцією вихідного тракту. Крім того, у разі ГКМП необхідно вчасно вживати заходів із профілактики та лікування у пацієнтів, котрі мають ризик раптової серцевої смерті. Оскільки ГКМП охоплює декілька діагнозів із патогенезом, що відрізняється, та різним лікуванням, то, відповідно до рекомендацій, необхідним може бути виконання МРТ серця, визначення рівня ферментів або генетичне тестування.

ГКМП – відносно поширене спадкове захворювання серця, і тому в щоденній клінічній практиці сімейних лікарів буде чимало таких пацієнтів. Отже, клініцисти мають припускати цей діагноз у пацієнтів з АГ, у яких маса лівого шлуночка відповідає критеріям ГКМП.

Hypertrophic cardiomyopathy (HCM) is a common congenital cardiac condition [1]. Based on recent findings, considering genetic testing and magnetic resonance imaging (MRI) results, its prevalence is estimated to be at about 1 in 200 individuals [2], making it a frequent pathology in everyday clinical practice. The diagnostic criterion of the disorder is left ventricular hypertrophy (LVH) of 15 mm or greater, not attributable to other conditions [3].

At the same time, LVH is one of the consequences of arterial hypertension (AH) [4,5], which is the most widespread cardiovascular disease globally [6]. It should be noted that AH is a relatively common comorbidity in HCM affecting 35–50 % of patients [4,7]. Given the often prolonged absence of complaints and clinical signs in HCM [2], a patient may initially seek medical attention only after manifestations of AH. In such instances, the presence of LVH may be assigned to the exclusive diagnosis of AH, potentially leaving concomitant HCM undetected [7]. This situation may pose risks to patients, as certain medications used to manage AH can worsen left ventricular outflow tract (LVOT) obstruction [5,7], which is present in 40–70 % of patients with HCM [1,8].

It is also crucial to remember that patients with HCM are at risk of sudden cardiac death (SCD) [3,4,9]. Therefore, a risk assessment is a key component of managing all patients [3,4] followed by the potential implantation of an implantable cardioverter-defibrillator (ICD) if deemed necessary [5]. Hence, in AH patients with severe LVH and ambiguous findings on echocardiography (EchoCG), cardiac MRI would be beneficial to rule out concomitant HCM [4,6,7,10].

## Aim

To describe a clinical case and analyze the challenges in diagnosing HCM in a patient with concomitant AH.

## Materials and methods

The article presents the clinical case of HCM in the patient with concomitant AH that was observed in an ambulatory setting in the Municipal Enterprise “Dnipropetrovsk Regional Clinical Center for Diagnostics and Treatment” of Dnipropetrovsk Regional Council.

The patient gave written consent to present her case in the journal. The publication was approved by the Biomedical Ethics Commission of the Dnipro State Medical University (protocol No. 18, April 17, 2024).

## Results

**Clinical case.** A 66-year-old female N., complaining of exertional dyspnea, chest pain, and an increase in blood pressure up to 160/90 mmHg. She had a 10-year history of AH and had been taking angiotensin-converting enzyme (ACE) inhibitors and diuretics irregularly. For the previous 6 years, she had been experiencing chest pressure and shortness of breath during moderate physical activity. A family physician had made the diagnosis of coronary artery disease (CAD): stable angina, functional class (FC) II, AH, grade 2 chronic heart failure, FC II NYHA. Despite receiving treatment with nitrates, ACE inhibitors, beta-blockers, diuretics, aspirin, and statins, her symptoms had not improved.

Therefore, the patient was sent for further examinations by a cardiologist. There was no past medical history of SCD cases in relatives.

Objective examination showed a body weight of 86 kg, body height of 167 cm, BMI of 30.8 kg/m<sup>2</sup>, respiratory rate of 16 per minute, heart rate (HR) of 67 beats per minute (bpm), blood pressure of 150/80 mmHg. Lung auscultation revealed bilateral vesicular breath sounds without crackles. On percussion, the right cardiac border was along the right parasternal line, the upper – in the third intercostal space and the left – along the left midclavicular line. The rhythm was regular. Heart sounds were diminished, and a systolic murmur over the entire heart area with a punctum maximum at the apex was detected. There was mild bilateral lower extremity oedema. Other systems were unremarkable.

### Additional examinations

Biochemical blood tests: total cholesterol – 6.1 mmol/L, triglycerides – 2.7 mmol/L, high-density lipoproteins – 1.01 mmol/L, K – 4.2 mmol/L, Na – 142 mmol/L.

Electrocardiogram (ECG) (Fig. 1). ST segment depression in leads I, II, aVF, V5 – V6, elevation – in III, V1 – V4. Low R amplitude in V1 – V4. Amplitude signs of LVH.

An ECG monitoring (obligatory for SCD risk calculation [9]): sinus rhythm with episodes of sinus arrhythmia, daytime HR was 54–65–80 bpm, rarely increased gradually to 90–98 bpm, nighttime HR was 50–60 bpm with sinus arrhythmia. Single supraventricular extrasystoles. Single polymorphic ventricular extrasystoles. Transient I-degree AV block.

Transthoracic EchoCG (Fig. 2). Left atria: size – 4.7 cm, size index – 2.45 cm/m<sup>2</sup>, index area – 12.5 cm/m<sup>2</sup>; right atria: area – 21.7 cm<sup>2</sup>, index area – 11.3 cm/m<sup>2</sup>. Right ventricle: size – 2.7 cm; left ventricle: size – 4.0 cm, end-diastolic volume – 70 mm; end-systolic volume 22.32 mm, stroke volume – 47.68 mm, wall thickness – 1.27 cm; left ventricle mass index – 142 g/m<sup>2</sup>; interventricular septum thickness – 1.9 cm; ejection fraction – 68.11 %. Conclusion: HCM. Concentric LVH with moderate obstruction of LVOT with a mean gradient of 19 mmHg. Abnormal diastolic function of the right and left ventricles; decreased segmental systolic function of the left ventricle (Sm 5.6 cm/s).

Cardiac MRI (Fig. 3, 4): the ascending aorta diameter – 39 mm, the pulmonary artery trunk diameter – 29 mm; the interventricular septum thickness – 22 mm (reference range (RR) – 10 mm); the anterior wall thickness – 25 mm (RR – 10 mm); the LV lateral wall thickness – 22 mm (RR – 12 mm); the posterior wall thickness – 25 mm (RR – 10 mm); anterior papillary muscle thickness – up to 22 mm; the right ventricle anterior wall thickness – 12 mm; the signal from the myocardium was diffuse and inhomogeneous; an area of 20.32 cm with an isointense signal was on the top of the heart relative to the rest of myocardium. Conclusions: signs of left ventricular concentric HCM.

To rule out the diagnosis of angina pectoris, coronary angiography and catheterization of the right and left heart were performed. Conclusions: HCM with LVOT obstruction (35 mmHg peak gradient). Mild aortic stenosis with a gradient of 15 mmHg. Mitral insufficiency ++ with calcinosis ++. There were no coronary artery abnormalities.

Alpha-galactosidase and lyso-GL-3 levels were within reference values.

To calculate the risk for SCD and indications for ICD implantation, an HCM Risk-SCD calculator was used

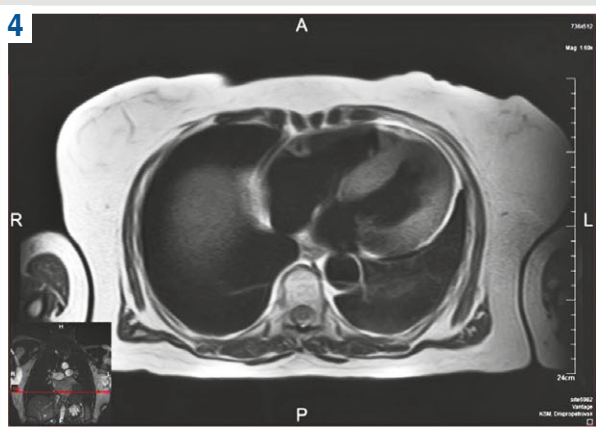
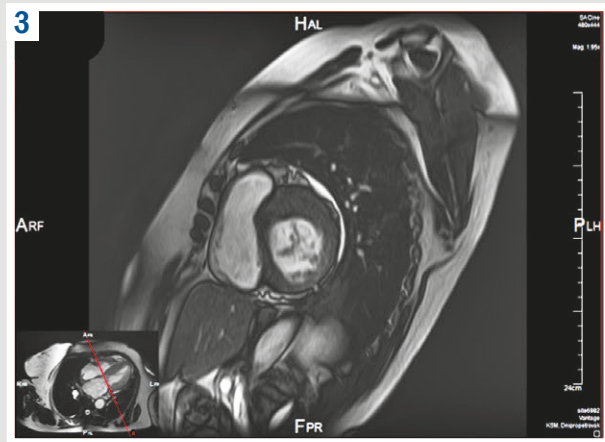
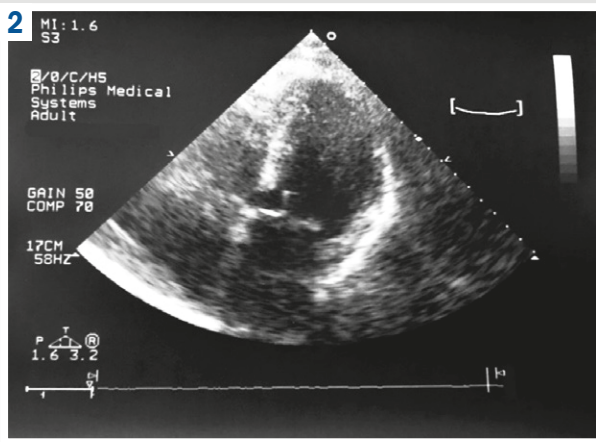
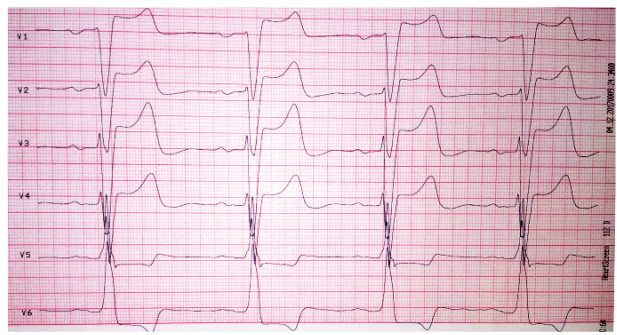
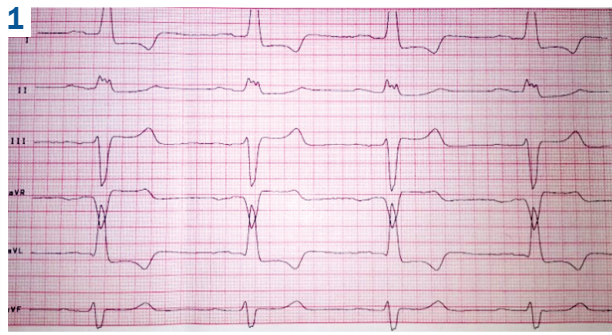


Fig. 1. Patient's ECG recorded during the visit to a cardiologist.

Fig. 2. Transthoracic EchoCG obtained during the visit to a cardiologist.

Fig. 3. MRI of the patient (longitudinal view).

Fig. 4. MRI of the patient (transverse view). Chest X-ray. Clear lung fields. Prominent lung hila. Free sinuses. LV enlargement. Sclerotic aorta.

considering the following data: patient's age, maximal left ventricular wall thickness, left atrium size, LVOT gradient, family history of SCD, the presence of unstable ventricular tachycardia and unspecified syncope episodes [3].

A calculated 5-year risk for SCD in the patient was 1.71 % corresponding to low risk, and ICD implantation was not indicated according to the ESC recommendations.

Clinical diagnosis. Based on the data obtained, the following clinical diagnosis was made: HCM with LVOT obstruction (maximum gradient 35 mmHg); grade 2 AH with LVH, risk group 3. Single supraventricular and polytopic ventricular extrasystoles. Transient I-degree AV block. Chronic heart failure with preserved left ventricular ejection fraction (ejection fraction – 68.11 %), NYHA II. Dyslipidemia. Stage I obesity.

According to guidelines for the management of HCM patients with chronic heart failure [3,8], AH [6], and for cardiovascular disease prevention in clinical practice [11], the treatment was based on using bisoprolol 5 mg once daily, spironolactone 25 mg once daily, and rosuvastatin 20 mg once daily. In addition, the patient was advised to reduce her calorie intake and increase physical activity under the guidance of a dietician and a physical therapist. The patient's condition improved in a month with the provided therapy: pain and dyspnea were absent, and her blood pressure was 130/85 mm/Hg.

### Discussion

Clinical presentation of HCM can vary, ranging from asymptomatic forms to severe symptoms [3]. In certain instances,

particularly when HCM manifests with mild or atypical features, it can go unnoticed without more active examinations, especially in patients with a known history of AH. In such cases, physicians may primarily focus on managing high blood pressure rather than considering other potential cardiac conditions such as HCM. This can lead to a tunnel vision approach, when symptoms or findings suggestive of HCM are attributed exclusively to AH.

Chest discomfort frequently presents as a symptom among individuals with HCM. For those with atherosclerotic coronary risk factors or for whom chest pain persists despite medical intervention, the potential presence of CAD needs to be considered. Coronary angiography proves beneficial in cases of HCM where the detection of CAD findings could inform patient management strategies [3,4,12]. In our case, this examination helped to rule out the presence of CAD.

Diagnosis of HCM often relies on a combination of clinical assessment, imaging methods (e. g., EchoCG), enzymatic and genetic testing [3,4]. In the described case, only ECG was performed in outpatient settings. However, both HCM and hypertension can lead to LVH with secondary repolarization abnormalities [5], making it difficult to differentiate between them based only on ECG findings. Moreover, despite the requirement for EchoCG in the guidelines for AH management [6], it was not ordered by a family physician. According to the clinical case analysis, this was the primary reason for delay in diagnosing HCM. EchoCG performed to our patient during the visit to the cardiologist revealed asymmetric hypertrophy with LVOT, both of which are diagnostic features of HCM [3,4]. But while EchoCG is a valuable tool in diagnosing HCM, particularly in detecting hypertrophy and assessing cardiac function, advanced imaging modalities such as cardiac MRI can provide additional diagnostic information [10]. Further important information can be provided with testing for alpha-galactosidase and lyso-GL-3 levels that are obligatory to rule out Fabry disease according to guidelines [3]. This is crucial because HCM encompasses various diagnoses that may require different approaches to management [3]. However, these diagnostic modalities can not be utilized without specific indications. That is why without a high index of suspicion for HCM in persons with AH, the diagnosis may be missed.

Another dangerous consequence of unrecognized HCM is an absence of obligatory SCD risk assessment which could be fatal to some patients [3,4,9,13].

One more essential moment to consider is the treatment of patients with the simultaneous presence of both disorders. AH management often involves strategies to reduce blood volume and peripheral vascular resistance [6], whereas in HCM, maintaining adequate preload and avoiding dehydration is critical for left ventricular filling [3,4]. It may be particularly fundamental, especially in cases of LVOT obstruction, as the prescription of certain first-choice medications according to the latest guidelines for the management of AH [6] could potentially exacerbate the degree of obstruction [3,4]. This might account to some extent for the complaints experienced by our patient, who was prescribed ACE inhibitors and diuretics, both of which must be used cautiously in cases of LVOT obstruction [3,4]. The treatment correction with the discontinuation of the mentioned medication resulted in the disappearance of complaints in our patient.

## Conclusions

1. It is especially important to follow the guidelines of AH management and perform echocardiography in all patients with high blood pressure, so as not to miss the signs of concomitant HCM, particularly with LVOT obstruction. It is vital because in such cases some first-choice drugs to treat AH should be avoided or used cautiously.

2. In addition, in the case of HCM, it is necessary to timely detect, provide prevention and manage patients at risk for sudden cardiac death. However, this point could be missed if the diagnosis is not suspected.

3. Since HCM encompasses various diagnoses with different pathogenesis and distinct management, cardiac MRI, enzymatic or genetic testing may be needed according to guidelines. However, these diagnostic modalities are not routinely utilized in AH patients if HCM is not suspected.

4. As HCM is a relatively common inherited cardiac disease, general practitioners could often encounter such patients in everyday clinical practice. Hence, they should have a certain suspicion of this diagnosis in persons with AH whose left ventricular mass meets the criteria for HCM.

**Conflicts of interest:** authors have no conflict of interest to declare.  
**Конфлікт інтересів:** відсутній.

Надійшла до редакції / Received: 26.04.2024

Після доопрацювання / Revised: 14.05.2024

Схвалено до друку / Accepted: 29.05.2024

## Information about the authors:

Khaniukov O. O., MD, PhD, DSc, Professor, Head of the Department of Internal Medicine 3, Dnipro State Medical University, Ukraine.

ORCID ID: 0000-0003-4146-0110

Sapozhnychenko L. V., MD, PhD, Associate Professor of the Department of Internal Medicine 3, Dnipro State Medical University, Ukraine.

ORCID ID: 0000-0002-6472-2235

Smolianova O. V., MD, PhD, Assistant of the Department of Internal Medicine 3, Dnipro State Medical University, Ukraine.

ORCID ID: 0000-0002-8654-381X

## Відомості про авторів:

Ханюков О. О., д-р мед. наук, професор, зав. каф. внутрішньої медицини 3, Дніпровський державний медичний університет, Україна.

Сапожниченко Л. В., канд. мед. наук, доцент каф. внутрішньої медицини 3, Дніпровський державний медичний університет, Україна.

Смольянова О. В., д-р філософії за спеціальністю 222 «Медицина», асистент каф. внутрішньої медицини 3, Дніпровський державний медичний університет, Україна.

## References

1. Maron BJ. Clinical Course and Management of Hypertrophic Cardiomyopathy. *N Engl J Med.* 2018 Aug 16;379(7):655-668. doi: [10.1056/NEJMra1710575](https://doi.org/10.1056/NEJMra1710575)
2. Pasqualucci D, Iacovoni A, Palmieri V, De Maria R, Iacoviello M, Battistoni I, et al. Epidemiology of cardiomyopathies: essential context knowledge for a tailored clinical work-up. *Eur J Prev Cardiol.* 2022;29(8):1190-9. doi: [10.1093/eurjpc/zwaa035](https://doi.org/10.1093/eurjpc/zwaa035)
3. Arbelo E, Protonotarios A, Gimeno JR, Arbustini E, Barriales-Villa R, Basso C, et al. 2023 ESC Guidelines for the management of cardiomyopathies. *Eur Heart J.* 2023;44(37):3503-626. doi: [10.1093/eurheartj/ehad194](https://doi.org/10.1093/eurheartj/ehad194)
4. Ommen SR, Mital S, Burke MA, Day SM, Deswal A, Elliott P, et al. 2020 AHA/ACC Guideline for the Diagnosis and Treatment of Patients With

- Hypertrophic Cardiomyopathy: A Report of the American College of Cardiology/American Heart Association Joint Committee on Clinical Practice Guidelines. *Circulation*. 2020;142(25):e558-631. doi: [10.1161/cir.0000000000000937](https://doi.org/10.1161/cir.0000000000000937)
5. Sayin BY, Oto A. Left Ventricular Hypertrophy: Etiology-Based Therapeutic Options. *Cardiol Ther*. 2022;11(2):203-30. doi: [10.1007/s40119-022-00260-y](https://doi.org/10.1007/s40119-022-00260-y)
  6. Mancia G, Kreutz R, Brunström M, Burnier M, Grassi G, Januszewicz A, et al. 2023 ESH Guidelines for the management of arterial hypertension The Task Force for the management of arterial hypertension of the European Society of Hypertension: Endorsed by the International Society of Hypertension and the European Renal Association. *J Hypertens*. 2023;41(12):1874. doi: [10.1097/hjh.0000000000003480](https://doi.org/10.1097/hjh.0000000000003480)
  7. Arabadjian M, Nicolas B, Montgomery S, Pleasure M, Collins M, Reuter M, et al. Clinical course and outcomes in adults with co-occurring hypertrophic cardiomyopathy and hypertension: a scoping review protocol. *BMJ Open*. 2023;13(7):e075087. doi: [10.1136/bmjopen-2023-075087](https://doi.org/10.1136/bmjopen-2023-075087)
  8. Seferović PM, Polovina M, Bauersachs J, Arad M, Ben Gal T, Lund LH, et al. Heart failure in cardiomyopathies: a position paper from the Heart Failure Association of the European Society of Cardiology. *Eur J Heart Fail*. 2019;21(5):553-76. doi: [10.1002/ejhf.1461](https://doi.org/10.1002/ejhf.1461)
  9. Nielsen JC, Lin YJ, de Oliveira Figueiredo MJ, Sepelri Shamloo A, Alfie A, Boveda S, et al. European Heart Rhythm Association (EHRA)/Heart Rhythm Society (HRS)/Asia Pacific Heart Rhythm Society (APHRS)/Latin American Heart Rhythm Society (LAHRS) expert consensus on risk assessment in cardiac arrhythmias: use the right tool for the right outcome, in the right population. *EP Eur*. 2020;22(8):1147-8. doi: [10.1002/jea.12338](https://doi.org/10.1002/jea.12338)
  10. Menghoum N, Vos JL, Pouleur AC, Nijveldt R, Gerber BL. How to evaluate cardiomyopathies by cardiovascular magnetic resonance parametric mapping and late gadolinium enhancement. *Eur Heart J Cardiovasc Imaging*. 2022;23(5):587-9. doi: [10.1093/ehjci/jeac051](https://doi.org/10.1093/ehjci/jeac051)
  11. Visseren FL, Mach F, Smulders YM, Carballo D, Koskinas KC, Böck M, et al. 2021 ESC Guidelines on cardiovascular disease prevention in clinical practice. *Eur Heart J*. 2021;42(34):3227-337. doi: [10.1093/eurheartj/ehab484](https://doi.org/10.1093/eurheartj/ehab484)
  12. Shin YJ, Lee JH, Yoo JY, Kim JA, Jeon Y, Yoon YE, et al. Clinical significance of evaluating coronary atherosclerosis in adult patients with hypertrophic cardiomyopathy who have chest pain. *Eur Radiol*. 2019;29(9):4593-602. doi: [10.1007/s00330-018-5951-8](https://doi.org/10.1007/s00330-018-5951-8)
  13. Klopotoski M, Kukula K, Jamiolkowski J, Oreziak A, Dabrowski M, Chmielak Z, et al. Sudden cardiac death risk over time in HCM patients with implantable cardioverter-defibrillator. *J Clin Med*. 2022;11(6):1633. doi: [10.3390/jcm11061633](https://doi.org/10.3390/jcm11061633)